

CASE REPORT**GIANT BENIGN SCHWANNOMA OF THE ANTERIOR BASE OF THE SKULL
WITH SINONASAL AND PHARYNGEAL EXTENSION**

Authors: Foma Winga(1)*, Pegbessou Essobozou(1), Ahanogbe Kodjo Mensah Hobli(2), Dolou Warou(3), Amana Bathokedeou(1), Kpemissi Eyawèlohn(1)

Authors Affiliations: (1) Département of Otolaryngology and head and neck surgery of the Sylvanus Olympio Teaching Hospital of Lomé, (2) Department of Neurosurgery of the Sylvanus Olympio Teaching Hospital of Lomé (3) Department of ENT and head and neck surgery of Kara Teaching Hospital of Lomé.

ABSTRACT

Introduction: Schwannomas are tumors developed from Schwann cells present in the peripheral nerve sheaths. Their development both extra and intracranial is extremely rare.

Observation: We report the case of a 36-year-old man who consulted for sinonasal syndrome evolving over the past ten years in which explorations found a large benign schwannoma of the anterior base of the skull with sinonasal and pharyngeal extension. The excision was performed externally by Moure and Sébilleau with ENT and neurosurgery collaboration. The suites were simple.

Discussion: The present observation again raises the question of the exact origin of developing sinonasal and endocranial schwannomas. The origin of the lesion and our management conditions were discussed.

Conclusion: as for other authors, schwannoma should be considered in the diagnosis of skull base tumors. External surgery for extensive forms and ENT and neurosurgery collaboration help to minimize the risk of complications.

Keywords: schwannoma; sinonasal schwannoma; skull base tumor.

INTRODUCTION

Schwannomas are tumors developed from Schwann cells found in the peripheral nerve sheaths. Rare in the nasal cavities and associated cavities, schwannomas originate there at the expense of the myelin sheath of the branches of the trigeminal nerve and the autonomic nervous system [1]. Their development both extra and intracranial is extremely

rare [2, 3]. The anatomical complexity of the area and the absence of early symptoms sometimes lead to diagnostic delay [2]. We report a large benign schwannoma of the anterior base of the skull with sinonasal and pharyngeal extension while noting our management conditions.

Observation

It was about a 36-year-old man who consulted for a right nasal obstruction then bilateral of progressive aggravation for ten years associated with a mucopurulent rhinorrhea sometimes streaked with blood and with a progressive decrease of the smell. A first consultation had been made 3 years earlier and the patient had postponed the explorations for financial reasons. The progression was to complete nasal obstruction, anosmia and the onset of bilateral hypoacusis. Faced with the failure of repeated self-medication, the patient consulted again for management. He had no particular medical history. Physical examination noted good general condition, a pinkish, rounded, smooth mass filling the right nasal cavity (Figure 1a) with a mass effect on the nasal septum and bilateral purulent rhinorrhea (Figure 1b). This mass brushed against the oropharynx, bulging the soft palate. Otoscopy noted an appearance of bilateral seromucous otitis. The neurologic and ophthalmologic examination was normal. Injected craniofacial computed tomography (CT) showed a large, well-limited mass extending from the anterior cerebral fossa to the right nasal fossa and to the cavum with a large anteroposterior axis of 10cm and heterogeneous contrast uptake (Figure 1c, 1d, 1e). Retentional filling of the paranasal sinuses was noted. Magnetic resonance imaging (MRI) could not be performed. A biopsy of the mass was taken and revealed a benign schwannoma of the nasal cavity. It should be noted the hemorrhagic nature of the lesion during the biopsy. The preoperative biological

assessment was unremarkable. The care consisted of bidisciplinary ENT and neurosurgical care in a humanitarian spirit. By the classic paralateronasal approach of Moure and Sébilleau, after removal of a maxillo-nasal bone flap, the mass was detached from the base of the skull at the stripper and then delivered on the finger via the first route (Figure 2a); the oropharyngeal passage being impossible. The endocranial part was detached from the frontal meninge at the curette through the defect of the cribriform plate. There was no cerebrospinal fluid leak. The purulent collections from the maxillary and sphenoid sinuses were aspirated with the buttoned cannula. After closure, the nasal cavities were wiped with two merocels 10 for 48 hours. The postoperative follow-up was straightforward with discharge from the hospital on D7, with the onset of the sensation of odors. Histological examination of the operative specimen confirmed the diagnosis of benign schwannoma (Figure 2b and 2c). At 1 year of follow-up, no complications were noted.

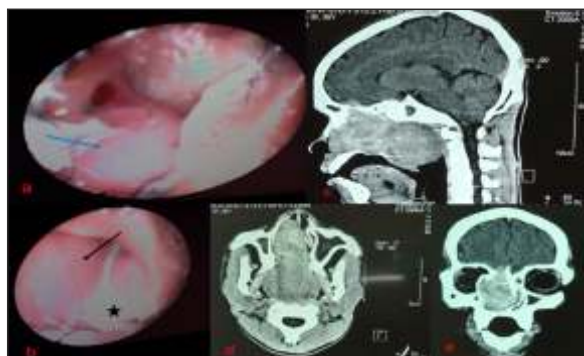


Figure 1: mass (blue arrow) filling the right nasal cavity (a) with mass effect on the nasal septum (black arrow) and purulent rhinorrhea (star) in the left nasal cavity (b). Sagittal (c), axial (d), and coronal (e) CT images showing a large, well-limited heterogeneous mass extending from the anterior cerebral fossa to the right nasal fossa and cavum.

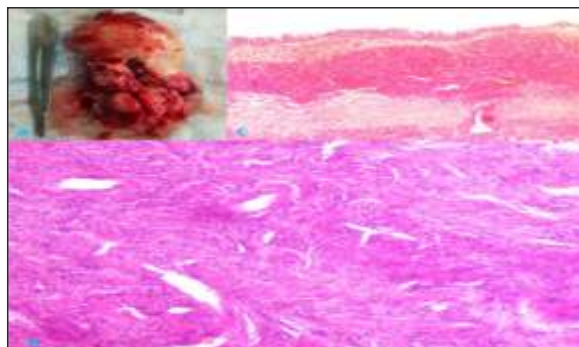


Figure2: Operative part (a). Histological section

showing hyperplastic nerve bundles forming dense bundles, entangled and interspersed by fibroblastic elements forming collagen; in places, the bundles organize themselves into palisades forming nodules (b). Histological section showing a lining mucosa, respiratory type (c).

DISCUSSION

The present observation, which is a first in our practice, although having its own characteristics, brings to light already known aspects of benign sinonasal schwannomas: slow evolution [3-6], sinonasal symptoms such as nasal obstruction, rhinorrhea, epistaxis, odor disorders, hemorrhagic character of biopsies [7, 8], external excision for large lesions [1] and good postoperative prognosis if complete excision [2, 9].

The present finding again raises the question of the exact origin of developing sinonasal and endocranial schwannomas [10]. In our observation, we believe that the nerve element that causes schwannoma must exist alongside the frontal meninges and the ethmoid. Schwann cell hyperplasia of a perivascular nerve plexus, of the meningeal branch of the trigeminal nerve in the anterior cranial fossa, of the anterior ethmoidal nerve around the cribriform plate, of the filia of the olfactory nerves is often mentioned in the occurrence of schwannomas the anterior fossa and the olfactory groove [3, 6]. It should be noted that the olfactory origin is exceptionally incriminated due to the myelination of the central type of the olfactory nerves which are considered, along with the optic nerves, as extensions of the central nervous system; their myelination being ensured by oligodendrocytes [11-13]. The absence of exploration by MRI was a limitation of our management because it would allow us to better appreciate the endocranial relationships of the lesion. Nasofibroscope, CT, and MRI can analyze the extensions and guide the surgical approach [7]. MRI is currently emerging as the gold standard for exploring skull base tumors [14]. The limited extension in the anterior fossa, the benign features and the high cost of MRI were to the detriment of the latter in our treatment. The external approach giving sufficient light on the lesion and the ENT and neurosurgical collaboration were decisive in minimizing the risk of complications in our patient.

CONCLUSION

The first case described in Togo, benign schwannoma of the base of the skull with extra and intracranial

extension is extremely rare. As with other authors, schwannoma should be considered in the diagnosis of skull base tumors. External surgery for extensive forms and ENT and neurosurgery collaboration help to minimize the risk of complications.

REFERENCES

1. Facon F, Forman C, Paris J, Chapon F, Moulin G, Dessi P. A Case of Nasal Septum Schwannoma: Endoscopic Resection. *Ann Otolaryngol Chir Cervicofac* 2004;121(3) : 179-183
2. Sharma R, Tyagi I, Banerjee D, Pandey R. Nasoethmoid schwannoma with intracranial extension. Case report and review of literature. *Neurosurg Rev* 1998;21(1):58-61.
3. Sunaryo PL, Svider PF, Husain Q, Choudhry OJ, Eloy JA, Liu JK. Schwannomas of the sinonasal tract and anterior skull base: A systematic review of 94 cases. *Am J Rhinol Allergy* 2014;28:39-49.
4. George KJ, Price R. Nasoethmoid schwannoma with intracranial extension. Case report and review of literature. *Br J Neurosurg* 2009;23(1):83-5.
5. Ansari I, Ansari A, Graison AA, Patil AJ, Joshi H. Head and Neck Schwannomas: A Surgical Challenge - A Series of 5 Cases. *Case Rep Otolaryngol* 2018, <https://doi.org/10.1155/2018/4074905>
6. Sauvaget F, François P, Ben Ismail M, Thomas C, Velut S. Anterior fossa schwannoma mimicking an olfactory groove meningioma: Case report and literature review. *Neurochirurgie* 2013;59:75-80.
7. Wong E, Kong J, Oh L, Cox D, Forer M. Giant Primary Schwannoma of the Left Nasal Cavity and Ethmoid Sinus. *Case Rep Otolaryngol* 2016, <http://dx.doi.org/10.1155/2016/1706915>
8. Shugar MA, Montgomery WW, Reardon EJ. Management of paranasal sinus schwannomas. *Ann Otol Rhinol Laryngol* 1982;91:65-9.
9. Kumar S, Sayoo C. Sinonasal Schwannoma: A Rare Sinonasal Neoplasm. *Indian J Otolaryngol Head Neck Surg* 2017;69(3):425-7.
10. Hazarika P, Nayak DR, Pujary K, Rao L. Schwannoma of the nose and paranasal sinuses. *Indian J Otolaryngol Head Neck Surg* 2003;55(1):34-8.
11. Leruez S, Gohier P, Menei P, Milea D. Schwannome du nerf optique. *J Fr Opht* 2013;36:e49-e53.
12. Guclu B, Meyronet D, Simon É, Streichenberger N, Sindou M, Mertens P. Anatomie structurelle des nerfs crâniens (V, VII, VIII, IX, X). *Neurochirurgie* 2009;55(5):92-8.
13. Leboucq N, Menjot de Champfleury N, Menjot de Champfleury S, Bonafé A. The olfactory system. *Diagn Interv Imaging* 2013;94(10):985-91.
14. Pierot L, Boulin A, Guillaume A, Pombourcq F. Imagerie des tumeurs de la base du crâne de l'adulte. *J Radiol* 2002;83:1719-34.

*Corresponding author:

Dr FOMA Winga
08BP: 80787, Lomé (TOGO)
E-mail: adrienfoma@yahoo.fr
Phone: 00228 90 87 48 90
ORCID ID: 0000-0003-1420-5675

How to cite the article

Winga F, Essobozou P, Mensah Hobli AK, Warou D, Bathokedeou A, Eyawèlohn K- Giant benign schwannoma of the anterior base of the skull With sinonasal and pharyngeal extension- UPJOHNS- Vol.-9, Issue-I, June 2021
DOI: <http://doi.org/10.36611/upjohns/volume9/Issue1/7>